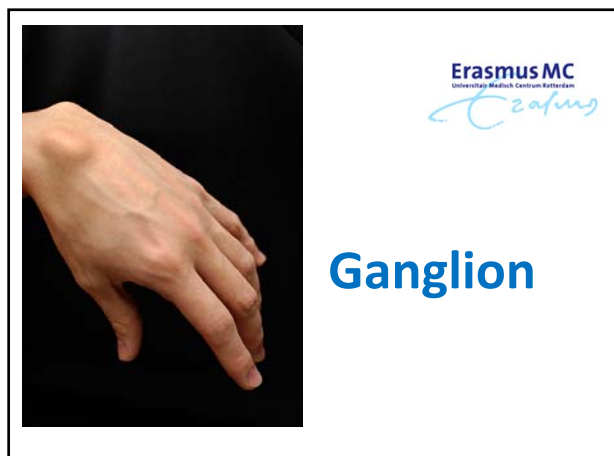

## NHG-Richtlijnen

Update 2021

- ❖ Bij een **ganglion** wordt aspiratie pro diagnosi ontraden, omdat het beloop na deze behandeling niet anders is dan bij afwachtend beleid.
- ❖ Gebruik diafanie bij diafanoscopie bij twijfel over de diagnose en vraag zo nodig echografie aan.

## Ganglion

uitstulping van het gewrichtskapsel of van de peesschede die gevuld is met synoviale vloeistof.

## Ganglion cyste

A ganglion cyst can occur...

...on the back of the wrist. ...on the palm side of the wrist. ...at the base of a finger.

Goedaardige zwelling die meestal op de bovenkant van de pols ontstaat

Soms aan de onderkant, maar ook in kleinere vorm in de vingers kan voorkomen (buigpees ganglion en mucoïde cyste).

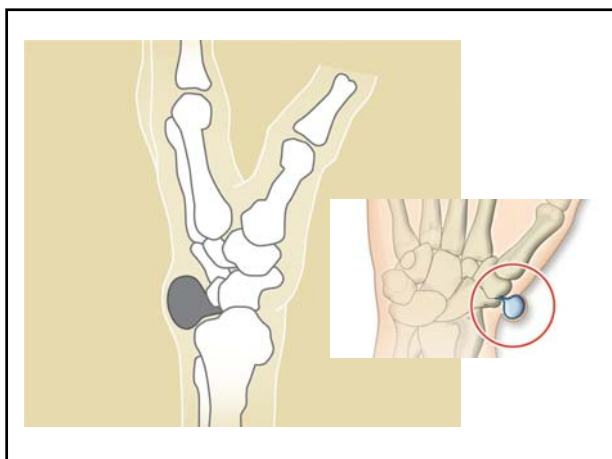
## diafanie bij diafanoscopie

### ganglion cyst light test

## Symptomen

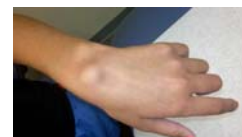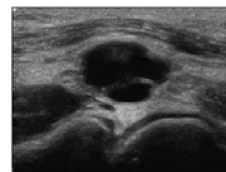
- opeens zijn, maar ook geleidelijk ontstaan
- meestal geen klachten
- 'in de weg zitten', een zeurend gevoel geven of bij bepaalde bewegingen pijn doen.

Soms wordt een Röntgenfoto gemaakt om onderliggende gewrichtslijtage uit te sluiten.



## Ontstaan

- oorzaak onduidelijk
  - icm artrose
  - beschadiging van banden rond de pols
  - hypermobiliteit
  - na fractuur
- Geen samenhang tussen ontstaan van ganglion en werk of hobby's.




## Behandeling

- Niets doen
- Aspiratie - leegzuigen
- Kapotdrukken (crushen)
- 'doorprikken' van het ganglion



[https://www.youtube.com/watch?v=ak\\_V2500HIM](https://www.youtube.com/watch?v=ak_V2500HIM)

## Behandeling



AMC/ Videler protocol

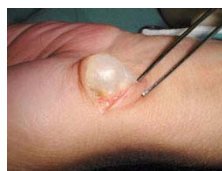The Birmingham Wrist Instability Programme

## Behandeling

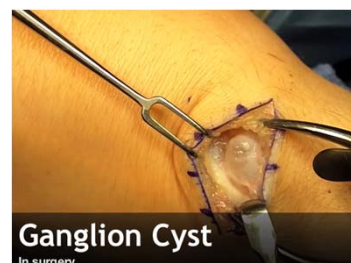leegzuigen, heldere, stroperige vloeistof verwijderd

Operatie  
Eventuele onderliggende gewrichtsafwijkingen moeten natuurlijk in voorkomend geval tegelijkertijd behandeld worden.

De nabehandeling bestaat uit 1-2 weken gips, waarna de hand weer gewoon ingeschakeld kan worden.



## Behandeling - operatie



<https://www.youtube.com/watch?v=gLswfkz0Pg>

## Postoperatieve behandelng

Tendon gliding exercises

© Healthwise, Incorporated

**INTER-CARPAL SOFT TISSUE ENTRAPMENT: A POSSIBLE EXPLANATION FOR CHRONIC DORSAL WRIST PAIN**

S. C. A. HONG, A. C. KUYPER and A. R. BOUW

*From the Department of Orthopaedics, Rheumatology and Hand Surgery, Radboud University Medical Center, Nijmegen, The Netherlands; and the Department of Hand Surgery, Radboud University Medical Center, Nijmegen, The Netherlands*

This retrospective study evaluates the surgical treatment of a group of patients with unknown chronic dorsal wrist pain. The cause of their symptoms was interpreted as a partial entrapment of flexor tendons in the radio-carpal and inter-carpal joints during specific movements. Between 1987 and 2007, 19 patients were treated by surgical release of the flexor tendons and the patients were treated for follow-up. In most cases patients were symptom free, or experienced major benefit from surgery. Wrist function measurements using the DASH scale showed improvement in 17 patients. Macroscopic examination of the released specimens shows flexor tendons with non-specific changes. Inter-carpal and inter-carpal ligaments can trap the tendons of the flexor tendons, in some patients with unknown chronic dorsal wrist pain. Their clinical features, surgical treatment and the management of the radio-carpal and inter-carpal joints may give a wider view of pain and improvement of wrist function. *Journal of Hand Surgery, British and European Volume, 2010; 35(B): 1-10*

**JHS(E)**

The Journal of Hand Surgery  
European Volume  
© The Author(s) 2021  
Reprints and permissions:  
permissions.doi.org/10.1007/s10864-020-00368-0  
SAGE

Full length article

### Ganglions of the hand and wrist: determinants of treatment choice

**F. Peters**  
Department of Orthopaedic Surgery, Massachusetts General Hospital, Boston, MA, USA

**A.-M. Vranceanu**  
Department of Biomedical Medicine, Massachusetts General Hospital, Boston, MA, USA

**M. Elben and D. Ring**  
Department of Orthopaedic Surgery, Massachusetts General Hospital, Boston, MA, USA

**Abstract**  
The aim of this study was to determine whether psychological factors (depression, catastrophic thinking, and pain anxiety) and pain intensity are associated with choice of operative treatment. Ninety seven patients with a ganglion cyst on their hand or wrist completed psychological questionnaires (Pain Catastrophizing Scale, Pain Anxiety Symptoms Scale, and Center for the Epidemiological Study of Depression instrument) and an ordinal measure of pain intensity. After a minimum of 4 months, patients were contacted to determine if they chose operative treatment, to rate their pain intensity, and to complete the Disabilities of the Arm, Shoulder, and Hand questionnaire. Younger patients were more likely to choose operative treatment. Psychological factors were associated with pain intensity at enrollment, but not with treatment choice. Operative treatment did not result in less pain intensity or disability, or higher satisfaction compared with non-operative treatment.

Operative treatment **did not** result in less pain intensity or disability, or higher satisfaction compared with non-operative treatment.

Evaluatie via email (noodzakelijk voor accreditatie)

Hand-out van presentaties via HandWeb pagina (link wordt verstuurd)

Video's via HandWeb YouTube kanaal

Module 2 basis – Trauma's van de hand en pols –  
Donderdag 22 april 2021